



## Acute Toxicity Test of White Turmeric Extract (*Curcuma Zedoaria*) on Female Wistar Rat Endometrium

Fiska Maya Wardhani<sup>1\*</sup>, Audrey Gracella Florenza<sup>2</sup>, Erny Tandanu<sup>3</sup>, Azizoglu<sup>4</sup>

<sup>1</sup>Departemen Histologi, Fakultas Kedokteran, Kedokteran Gigi, dan Ilmu Kesehatan, Universitas Prima Indonesia

<sup>2</sup>Program Studi Pendidikan Dokter (S1), Fakultas Kedokteran, Kedokteran Gigi, dan Ilmu Kesehatan, Universitas Prima Indonesia

<sup>3</sup>Departemen Farmakologi, Fakultas Kedokteran, Kedokteran Gigi, dan Ilmu Kesehatan, Universitas Prima Indonesia

<sup>4</sup>Dicle University Medical school Department of Pediatric Surgery and head of PesMA study group, Diyarbakir, Turkey

\*Corresponding Author: Fiska Maya Wardhani

Email: [drfiska.mw@gmail.com](mailto:drfiska.mw@gmail.com)



### Article Info

#### Article history:

Received 12 September 2023

Received in revised form 25 September 2023

Accepted 10 October 2023

#### Keywords:

Acute Toxicity Test

Endometrium

White Turmeric Extract

### Abstract

Indonesia is a country that has very abundant natural biota resources. There are many types of plants that are often used in traditional medicine. One of the plants that is often used is white turmeric (*Curcuma zedoaria*). This study aimed to identify the toxic effects and determine the LD50 value of white turmeric extract. In this study, rats were divided into six groups with per-oral administration of the extract. After the administration of the extract, 24 hours of toxicity symptoms were observed, then the number of dead rats was recorded. On the 15th day, uterine organs were taken for histopathology observation. Based on the results of the tests that have been carried out, no toxic effects were found in rats, with a pseudo-LD50 value of  $>2000\text{mg/kgBB}$ . The conclusion of this study was that there is no significant difference in endometrial histopathology such as epithelial proliferation at a dose of  $2000\text{mg/kgBW}$  white turmeric extract with other groups ( $p=0.529$ ).

## Introduction

Indonesia is a country that has very abundant natural biota resources. There are many types of plants that can be used as ingredients for making traditional medicine. Traditional medicinal plants are natural materials that are used for treatment based on experience passed down from generation to generation (Maulidiah, 2019).

White turmeric (*Curcuma zedoaria*) is one type of various traditional medicinal plants that are free to use to treat various health problems. White turmeric has a morphology, namely white tubers with yellow rhizomes and round like eggs (Silalahi, 2020). White turmeric contains 1-2.5% essential oil consisting of monoterpenes, epikurminol, curcumin, zingiberene, and kurzerenon (Zedoarin) (Rita, 2010). White turmeric has properties such as anti-inflammatory, anti-cholesterol, anti-tumor / cancer, anti-microbial, analgesic, and antipyretic (Silalahi, 2020).

The essential oil content in white turmeric has an analgetic effect so that it can reduce the intensity of pain during menstruation by reducing the excretion of prostaglandins (Sari et al., 2020). In addition, the content of flavonoids and curcuminoids obtained through ethanol extract can help cure cancer and has anticancer activity against Hela cells, so it is considered equivalent to the cancer drug Cisplatin (Sumantri, 2018). The role of curcumin in endometriosis is as a

regulator in the inflammatory process, suppressing free radicals such as ROS and nitrogen dioxide, and inhibiting the process of angiogenesis (Vallée & Lecarpentier, 2020).

Giving turmeric extract to rats in the gestation period had a bad impact. Judging from the histological picture is endometrial thinning, which causes a decrease in the development of pregnancy, a decrease in the number of implantations and a decrease in the number of live fetuses in mice. This can trigger abortion in pregnancy (Titiglory & Kristanto, 2016). Administration of antioxidants can suppress the side effects of long-term use of synthetic estrogens. Antioxidants can suppress free radical levels, so as to prevent damage to ovarian cell membranes and endometrium (Raharjo et al., 2018). This shows that the content of white turmeric extract can be an alternative to overcome various diseases.

Toxicity test is a test that aims to see the efficacy of both test materials and also to find out certain doses that can be used safely for the body and effective use (Wardhani et al., 2022). Because the presence of curcumin content can affect the picture of endometrial epithelial proliferation, this study aims to determine the acute toxic dose of white turmeric extract (*Curcuma zedoaria*) against the uterus. What is observed is a change in the histopathological picture of the endometrium, in the form of epithelial proliferation and tissue necrosis (Raharjo et al., 2018).

## Methodology

This study used the post test only control group design. This study used samples with criteria, namely white rats (*Rattus norvegicus*) healthy females, not in the gestation period, aged 4-6 months with a body weight of about 200-300 grams. The number of test animals in this study was 30 white rats which were grouped into 6 treatment groups, namely; (1) The normal control group was given aquadest; (2) The negative control group was given a solution of Na CMC; (3) Treatment Group 1 was given a solution of white turmeric extract at a dose of 250 mg / KgBB; (4) Treatment Group 2 was given a solution of white turmeric extract at a dose of 500 mg / kg body weight; (5) Treatment Group 3 was given a solution of white turmeric extract at a dose of 750 mg / kg BB; (6) Treatment group 4 was given a solution of white turmeric extract at a dose of 2000mg/KgBB (Erny et al., 2022). The independent variable is an acute toxicity test by dosing white turmeric extract and the dependent variable is the histopathological picture of the endometrium of white rats. This research will take place at the Pharmacology Laboratory and Histology Laboratory, Faculty of Medicine, University of North Sumatra in March 2023. This research has passed the Health Research Code of Ethics (KEPK) of Universitas Prima Indonesia with the number KEPK/UNPRI/III/2023.

## Materials and Tools

The test material used in this study was white turmeric rhizomes obtained through UPT Materia Medica Batu, East Java. Oral administration of turmeric extract. Observation during the first 24 hours to see symptoms of toxicity that appear on fur, skin, eyes, diarrhea, tremors, convulsions, and death. On day 15, the rats were weighed first and then sacrificed using ether for uterine organ harvesting. The organ is put in a pot of 10% formalin.

Staining of histopathological preparations using Haematoxylin Eosin (HE). Histopathological observations of uterine tissue from each preparation were then observed using a light microscope with five different views at magnifications of 100x and 400x. Microscopic observations were made to see whether there were changes in the endometrial structure of the administration of white turmeric extract. The observed changes are endometrial epithelial proliferation and tissue necrosis. This assessment is based on the endometrial histopathology scoring method in Table 1.

## Data Analysis

With the computer SPSS program, the data obtained were processed with normality tests using Saphiro-Wilk and continued Kruskal-Wallis testing to determine whether there were significant differences between the normal group and Na CMC with the treatment group with doses of white turmeric extract (250 mg / kg BB, 500 mg / kg BB, 750 mg / kg BB and 2000 mg / kg BB).

## Results and Discussion

From the results of observations made within 14 days, white rats given white turmeric extract did not cause death. The condition of the rats such as eyes, fur, and skin is visible in normal conditions. No toxic symptoms were found in rats such as skin disorders, diarrhea, tremors, lethargy, or seizures in each group. The results of endometrial histopathology observations from each treatment group found epithelial proliferation in the endometrium which can be seen in Figure 1. The average results of endometrial histopathology scores in each treatment group found minimal changes in the endometrium that were not significant (Table 2). The results of the Saphiro-Wilk normality test show that the data is not normally distributed ( $p < 0.005$ ). Therefore, data processing is continued using the Kruskal-Wallis test. From the results of the Kruskal-Wallis test, there was no significant difference between treatment groups ( $p = 0.529$ ).

Table 1. Scoring endometrial histopathologies (Raharjo et al., 2018)

Score	Damage Criteria	
	Epithelial Proliferation	Tissue Necrosis
0	No epithelial proliferation	No tissue necrosis
1	<25% proliferate epitel	There is, focal necrosis (mild)
2	25-50% epithelial proliferation	There is, multifocal necrosis (moderate)
3	>50% epithelial proliferation	There is, diffuse necrosis (severe)

Description: Epithelial Proliferation (👉)

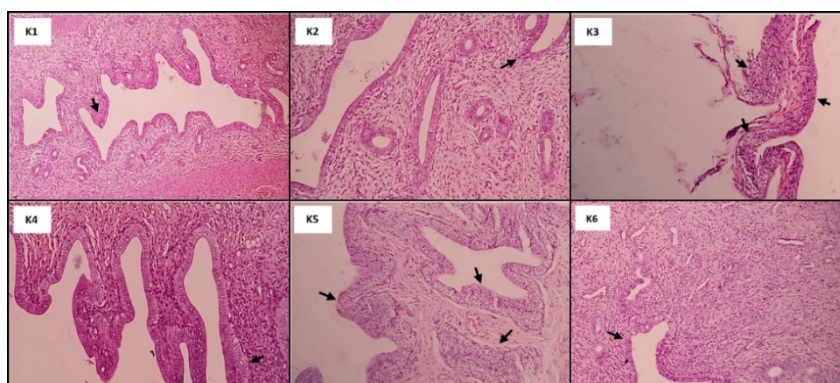


Figure 1. Histopathology of Rats Endometrium in Each Treatment

Table 2. Average Endometrial Histopathology

Group	Average±Standard Deviation
K1 (Normal Control)	1.00±0.000
K2 (CMC Na Control)	1.00±0.000
K3 (EKP 250mg/kgBB)	1.20±0.447
K4 (EKP 500mg/kgBB)	1.00±0.000
K5 (EKP 750mg/kgBB)	1.20±0.447
K6 (ECB 2000mg/kgBB)	1.00±0.000

The acute toxicity test aims to determine how the effect of the test preparation in a short time after being given the test material orally, either in a single dose or repeated doses within 24

hours. The results of the acute toxicity test will later determine LD50 (lethal dose 50%) in the test preparation. Results from the acute toxicity test of white turmeric extract found no symptoms of toxicity and death in rats given EKP doses of 250mg/kgBB to 2000mg/kgBB. With no deaths found in test animals, LD50 values cannot be calculated (Sulastra & Khaerati, 2020). White turmeric extract has an LD50 value of >2000 mg / kg BB, so it is included in the category of non-toxic compounds (Abrori et al., n.d.). If the maximum dose of 2000mg/kgBB does not cause toxic effects, it is declared pseudo LD50 (not actual LD50) (Sulastra & Khaerati, 2020). So it is considered that the apparent LD50 value in white turmeric rhizome extract is >2000mg/kgBB.

Giving doses of white turmeric extract up to a dose of 2000 mg / kg BB is considered safe against the endometrium of white rats because histopathological changes are mild and insignificant. Changes in microscopic images in rat endometrial studies in the gestation period showed a decrease in endometrial thickness (Raharjo et al., 2018). Giving turmeric extract can inhibit growth factors and hormones that play a role in the gestation period, so that it can cause a decrease in the number of implantations from fertilization, a decrease in the number of living fetuses, inhibit fetal growth, inhibit the formation of adrenal glands in rats, and can cause abortion in rats (Titiglory & Kristanto, 2016). White turmeric extract is used as an antioxidant, can prevent damage from cell membranes due to exposure to free radicals (Raharjo et al., 2018). Previous research has shown that curcumin content in white turmeric extract can inhibit the estrus cycle by lowering FSH and LH hormone levels, thereby increasing uterine weight and body weight in mice. Turmeric extract can be antifertility with antiovarian activity that has antiestrogenic properties (Purwaningsih, 2016).

The phytoestrogen content in turmeric can stimulate progesterone stimulation in the ovaries, produce estradiol and cAMP, and help oocyte maturation and zygote development in the pre-implantation stage. Curcumin can inhibit free radicals by inhibiting lipid peroxidase and nitrogen dioxide expression, and regulate endometrial thickening by modulating VEGF expression (Vallée & Lecarpentier, 2020). From the results of the study, it was found that epithelial proliferation occurred. Epithelial proliferation on the histopathological picture indicates a phase of secretion. The secretion phase has a picture of the occurrence of endometrial thickening due to the increase in the number of glands and blood vessels, as well as the increase in the production of leucocytes (Cunningham et al., 2010). In this phase the endometrium prepares its environment for implantation of the fertilized embryo (Narulita et al., 2017).

Limitations in this study were influenced by differences in the digestive process and absorption of turmeric rhizome extract in the gastrointestinal tract, and how much of the extract reached the target organ which was affected by metabolism in the liver so that it could affect ovulation (Metalloproteinase & Hastati, 2015). Other things that influenced this study were hormonal degrees in each white mouse, stress factors, and other internal factors such as genetic state, health and nutrition of each mouse (Titiglory & Kristanto., 2016).

## **Conclusion**

The conclusion in this study was that there was no significant difference in the endometrial histopathological picture of both endometrial epithelial proliferation and tissue necrosis at a dose of 2000 mg / kg body weight with other groups, so it was included in the category of non-toxic practices.

## **Suggestion**

From this study, further research can be carried out on subchronic and chronic toxicity tests using white turmeric extract, as well as research on the effect of white turmeric extract on estrogen and progesterone hormones.

## References

- Abrori, C., Nurfadhila, K., & Sakinah, E. N. (n.d.). Uji Toksisitas Akut Ekstrak Etanol Daun Kemangi (*Ocimumsanctum*) Diukur dari Nilai LD 50 Vol. 5 No. 1 (2019) *Journal of Agromedicine and Medical Sciences dan Histopatologi Ginjal (Acute Toxicity Tests of Basil Leaves (Ocimumsanctum) Ethanolic Extract Determined By LD 50 and Renal Histopathology)*.
- Cunningham, F. G., Leveno, K. J., Bloom, S. L., Hauth, J. C., Rouse, D. J., & Spong, C. Y. (2010). Labor and delivery. *Williams Obstetrics*, 374–577.
- Erny, T., Kewin, G., Fiska, W. M., & Rico, S. A. (2022). Acute toxicity of extract of white turmeric rhizome (*Curcuma zedoaria*) review of ld50 and blood cell components of white turmeric rhizome (*Curcuma zedoaria*) review of ld50 and blood cell components. *Medical Study Program, faculty*. 4. 594–603.
- Maulidiah, M. (2019). Utilization of Plant Organs as Traditionally Processed Medicine in Sugarcane Plantation District, West Lampung Regency. UIN Raden Intan Lampung.
- Metalloproteinase, D. A. N. M., & Hastati, S. R. I. (N.D.). *Effect Of Turmeric Extract*.
- Narulita, E., Concerned, J., Anam, K., & Oktavia, F. A. R. H. (2017). Changes in estradiol levels and uterine histology of female mice (*Mus musculus*) by synthetic progesterone induction. *BIOSFERA Biological Scientific Magazine: A Scientific Journal*, 34(3), 117–122.
- Purwaningsih, E. (2016). The potential of curcumin as an anti-fertility ingredient. *Yarsi Journal of Medicine*, 24(3), 203–211.
- Raharjo, Y. Y. C. Y. A., Samsuri, I., & Berata, I. K. (2018). Histopathological Features of White Rat Ovaries (*Rattus Norvegicus*) Due to Vitamin E and Ethinyl Estradiol. *English Medicus Veterinus*.
- Rita, W. S. (2010). Isolation, identification, and antibacterial activity test of triterpenoid group compounds in white rhizome (*Curcuma zedoaria* (Berg.) Roscoe). *Journal of Chemistry*, 4(1).
- Sari, D. N., Anwar, R., Rasyad, A. S., Wijayanegara, H., Supriadi, H., & Suardi, A. (2020). Effect of aqueous extract of white turmeric (*Curcuma zedoaria* roscoe) on the reduction of primary dysmenorrhea. *Journal of Health Systems*, 5(3).
- Silalahi, M. (2020). *Curcuma zedoaria* (Christm.) Roscoe: benefits and bioactivity. *Eureka Herba Indonesia*, 1(2), 41–48.
- Sulastra, C. S., & Khaerati, K. (2020). Acute toxicity and lethal dose (Ld50) ethanol extract of Uwi Banggai purple (*Dioscorea alata* L.) In White Rats (*Rattus norvegicus*). *Medicamento Scientific Journal*, 6(1).
- Sumantri, A. W. (2018). Effectiveness of anticancer fraction (*Curcuma zedoaria*) and its effect on caspase 3 gene expression in hela cells in vitro. *Prime Saelmakers Health Journal*, 1(2), 1–9.
- Titiglory, T. W., & Kristanto, H. (2016). Histopathological features of endometrial of Balb/C mice in the gestation period given sour turmeric extracts (*Curcuma domestica* and *Tamarindus indica*) at stratified doses. Diponegoro University.

- Vallée, A., & Lecarpentier, Y. (2020). Curcumin and endometriosis. *International Journal of Molecular Sciences*, 21(7), 2440.
- Wardhani, F. M., Ong, G. F., Virgoh, L., Lubis, A., & Nasution, M. H. (2022). Acute toxicity test of white turmeric extract against blood sugar and cholesterol levels. *Journal of Medicine and Health: Scientific Publications of the Faculty of Medicine, Sriwijaya University*, 9(3), 345–350.