



Identification of Forensic Odontology in Investigation Case of Human Skeletal Findings: Case Report

Fitri Rizki Amalia¹, Farah Primadani Kaurow², Nurtami Soedarsono³,
Elza Ibrahim Auerkari³

¹Forensic Odontology Specialist Study Program, Department of Oral Biology, Faculty of Dentistry, University of Indonesia, Indonesia.

²Forensic Medicine Department, Bhayangkara Tertiary Hospital, Jakarta, Indonesia.

³Division of Forensic Odontology, Department of Oral Biology, Faculty of Dentistry, University of Indonesia, Jakarta, Indonesia.

*Corresponding Author: Elza Ibrahim Auerkari
E-mail: auerkarie@gmail.com



Article Info

Article history:

Received 25 June 2025

Received in revised form 18 July 2025

Accepted 25 August 2025

Keywords:

Forensic Odontology

Skeletal Identification

Race And Gender

Determinaton Age Estimation

Abstract

The objective of forensic identification is to assist investigators in identifying an individual's identity. Through the identification process in forensic odontology, we can obtain information related to a person's identity such as race, gender, age and oral habits. This case report discusses the identification of skeletal found by residents in a garbage dump. This discovery was reported to the police in charge for further investigation. These skeletal were identified by a joint team, consist of forensic pathologist and forensic odontologist. In this case, we conclude the skeletal was human skeletal, mongoloid male with estimation of age between 30-50 years old.

Introduction

Every person's identity has been protected by law, specifically as outlined in Law Number 39 of 1999, Article 53, paragraph 2, which states that from birth, every child is entitled to a name and a citizenship status. In addition, Article 118 of Law Number 36 of 2009 concerning Health has given a mandate to the government and the community to make efforts to identify unknown bodies. (Henky & Safitry, 2012) (Republik Indonesia, 2009).

The concept of identification refers to the process of determining a person's identity through a set of characteristics, with the goal of verifying whether the individual matches a previously known person who was believed to possess those same characteristics. Identification holds significant meaning across both forensic and non-forensic contexts. (Amir A, 2013)

Individual identification can be done through several parameters, namely identification of age, race, and gender. Gender identification is an important first step in the forensic identification process because it can find a 50% probability of matching in individual identification and can affect several other examination methods, such as estimating the age and height of the individual. (Novitasari, Istiqomah, & Rizaldy, 2023)

There are 2 ways to collect data for identification: 1. Dental data, fingerprints, or DNA can be used as a determinant identification factor (primary identification). 2. While medical data, property and physical characteristics must be a combination of at least two types to be considered as a definite identity characteristic (secondary identification). In determining a

person's identification positively, namely at least if one of the primary identifiers and or supported by at least 2 secondary identifiers. (Amir A, 2013)

Estimation of sex, age, race and stature is an integral part of the biological profile used by forensic anthropology to assist in achieving identification of an individual from an unknown skeletal body. This biological profile consists of sex, age, ancestry, and stature estimates, which can be compared to missing person reports.(Franklin, 2010). Pelvic and cranial morphology will most predictably estimate sex, age is determined by dental development in the juvenile and degenerative changes in the adult. Ancestry is normally assessed through the craniofacial traits and craniometry and stature is calculated based on the size of the long-bones. Together, these anthropological estimates can be used to significantly reduce the scope of possible identities and are central in forensic investigations (Hughes et al., 2023).

Dental identification plays a crucial role in identifying the remains of a deceased individual, particularly when they are skeletonized, decomposed, burned, or dismembered, as visual or fingerprint methods can be challenging to apply in such situations. Remains identification through dental evidence is feasible due to the preservation of hard tissues after death, which can endure a temperature of 1600 degree C without significant loss of microscopic structure, and the unique changes in an individual's teeth throughout life - such as decay, missing teeth, and fillings - can be evaluated at any given point in time.(Divakar, 2017)

Dental identification divided into five types : (Chiam, Higgins, Colyvas, Page, & Taylor, 2021)

Positive or Identified

There is absolute certainty that ante-mortem and post-mortem data match, proving they belong to the same individual.

Probable

Comparable traits existed between postmortem and antemortem information, but either the data or both datasets were limited.

Possible identification

The antemortem and postmortem information share similar characteristics, but due to the poor quality of either the postmortem data or the antemortem data, it is not possible to definitively confirm dental identification.

Insufficient evidence

The available data is insufficient to draw a conclusion.

Exclusion

The ante-mortem and postmortem findings are manifestly contradictory.

Case Description

The body of an unidentified man was found in the garbage dump on the edge of Kalimalang, under the Becakayu Toll Flyover, Bekasi Selatan on 2023. The body was found in a state of decay almost like a as shown in Figure 1. To find out the identity and cause of death of the body, the police investigators from the local police sent a letter requesting a visum et repertum to the forensic doctor in Forensic Medicine Departement at Hospital. External inspection was carried out on 2023 and internal examination was carried out on 2024.

For forensic odontology examination, the operator examines and takes a photograph of the craniofacial morphology and dimensions : the morphology of the skull and lower jawbone. The dental findings also documented and analysed.



Figure 1. Skeletal findings identified as 1 individual

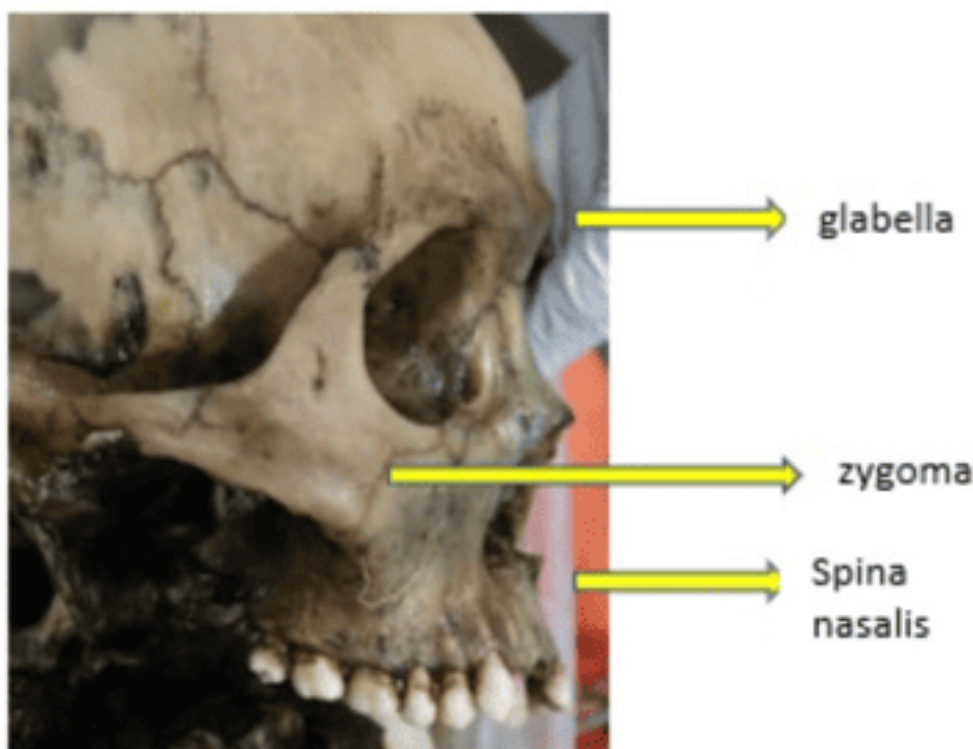


Figure 2. Side view of skull

In the body bag there was one skull and one mandible still attached with a few remnants of decomposed tissue. After the remaining tissue was cleaned and we separated the mandible, no fractures were found in the skull and lower jaw bones found. From the side view of skull (figure 2), we can find that the zygoma bone protruding forward, there is moderate spina nasalis, and protruding glabella bone. The mandibular arch tends to be wide and shaped like the letter 'U' (figure 3). The chin is wide (figure 4) in men, while in women it is pointed. (Burns, 2013)

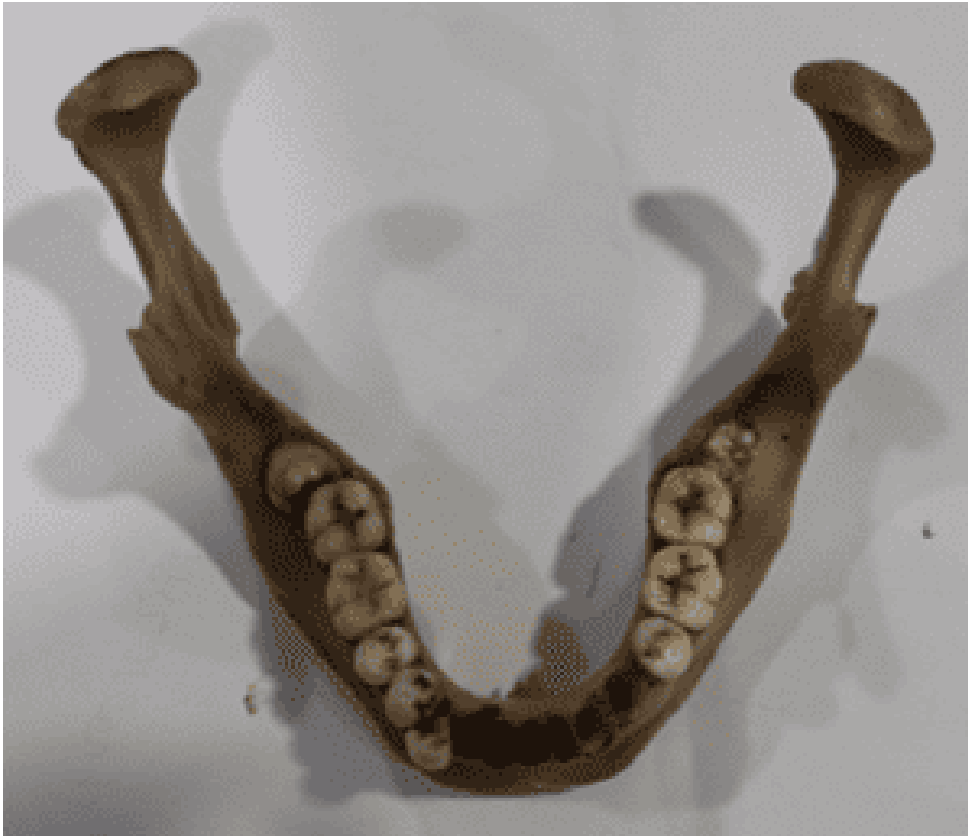

Figure 3. Oklusal view of mandible

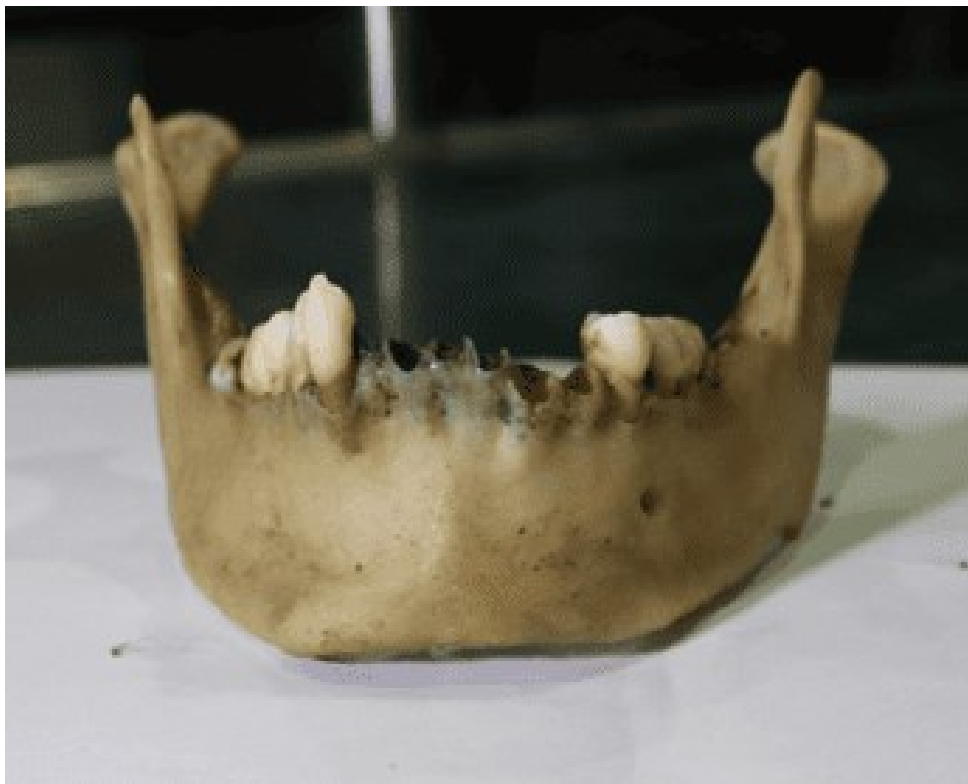

Figure 4. Front view of mandible

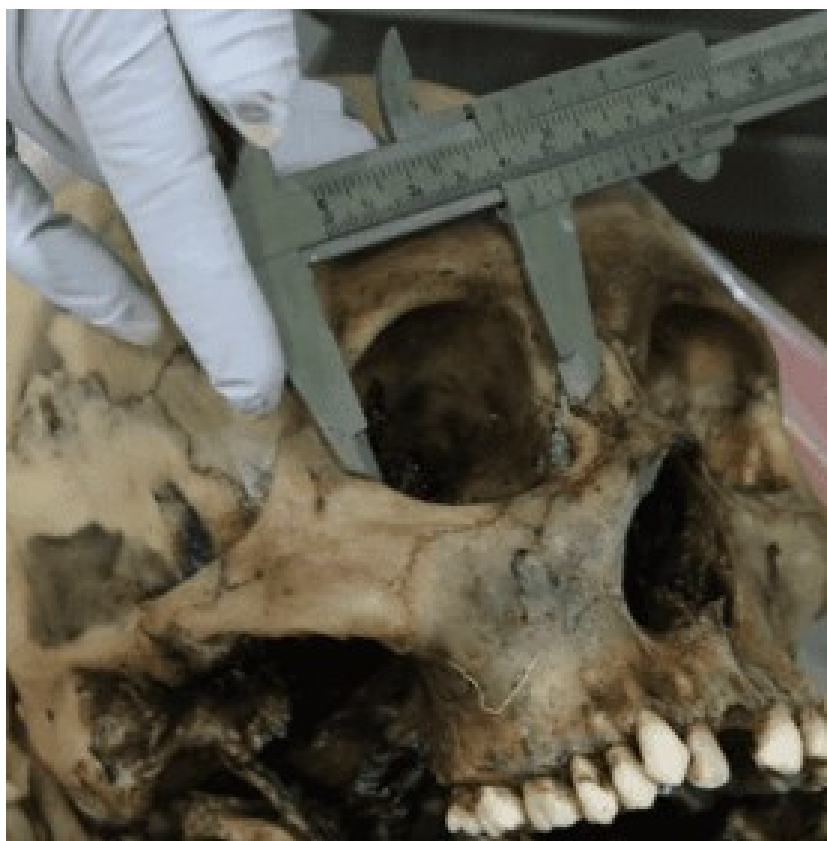

Figure 5. width of orbital bone

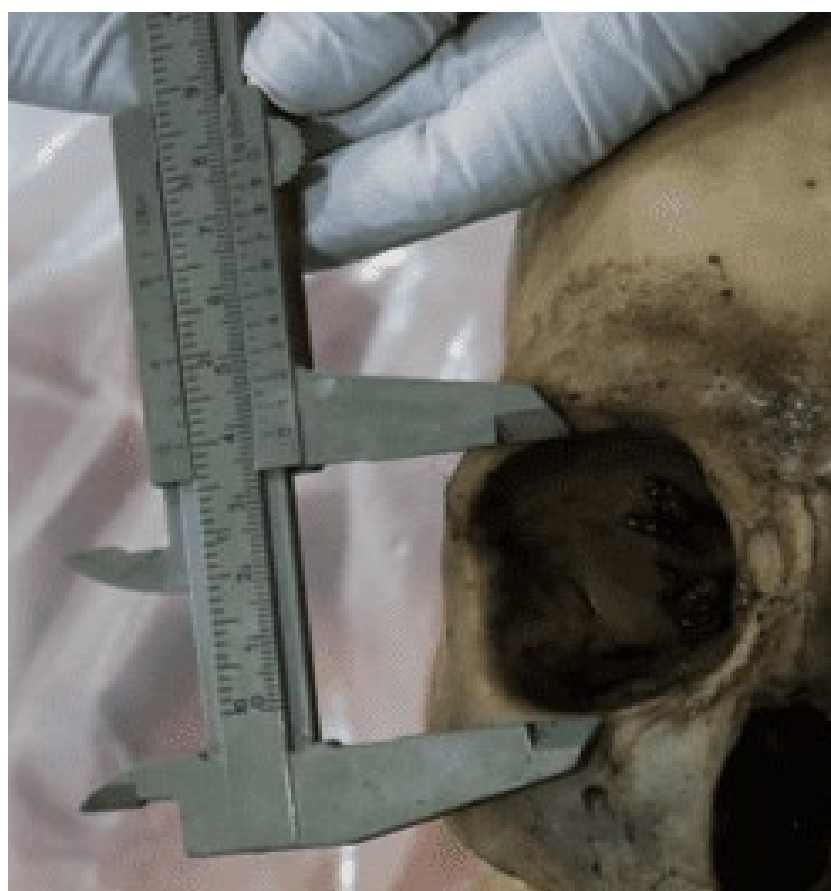

Figure 6. Height of orbital bone

The measurement result of orbital bone width are 41,5 mm (figure 5) and orbital bone height (figure 6) are 38,6 mm. From that we can count the orbital index (orbital bone height/orbital bone width X 100) and the result is 93 that categorized into Megesme. (Kumar & Nagar, 2014)

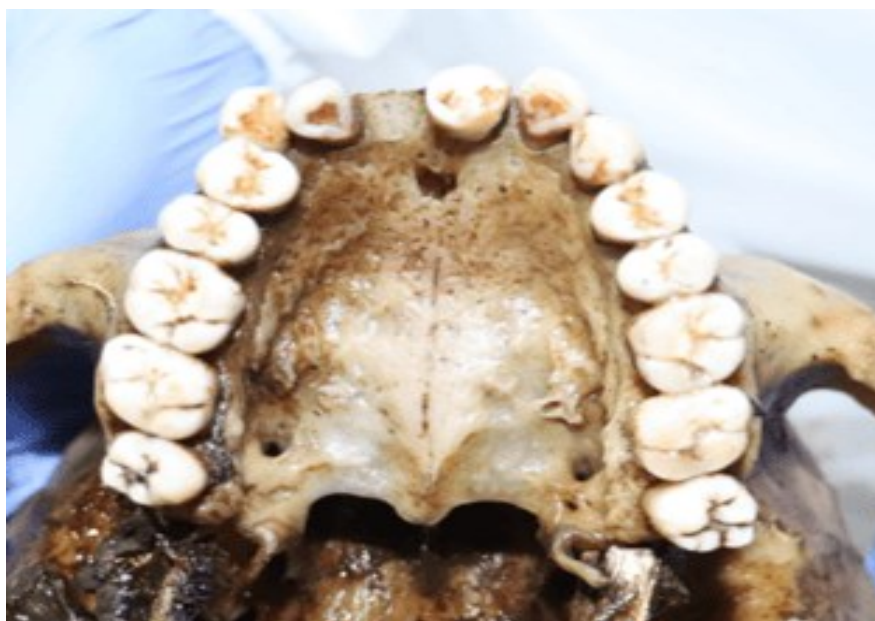

Figure 7. Dental findings in maxilla and view of palatina sutura

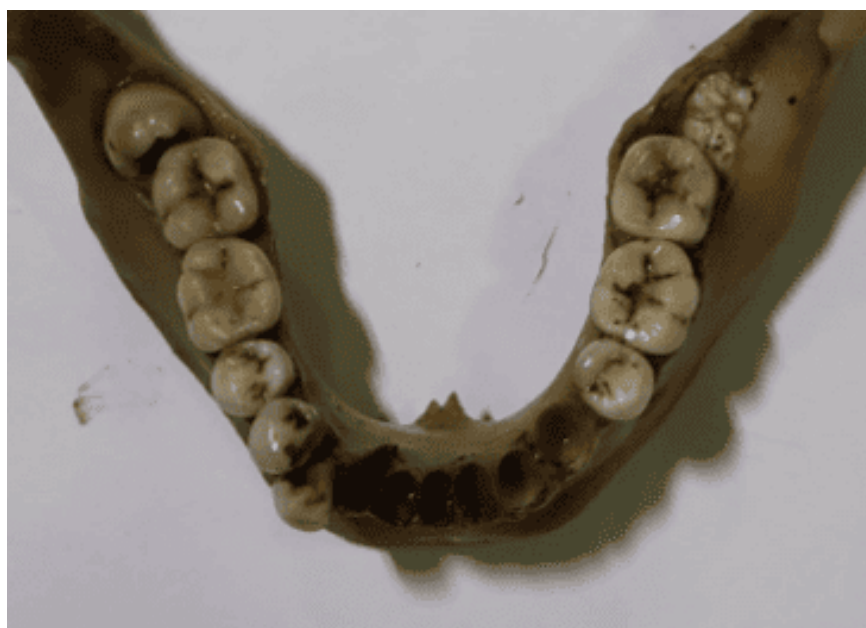


Figure 8. Dental findings in mandible

There were 15 teeth found in the upper jaw, including the mandibular first left premolar tooth that was not attached and incorrectly placed in the first incisor left maxillary socket. From the socket we know that right and left maxillary central incisor was missing post mortem, so the number of maxillary tooth found was 14 (figure 7). From figure 8 we could see there was 10 teeth that attached to mandible, and if we include the first left premolar tooth previously, so the number of mandible tooth found was 11. We could see the both third molar in mandible was impacted. The presence of the third molar tooth and the position of the maxillary third molar tooth whose occlusal surface is already parallel to the second molar tooth next to it indicates that the tooth has erupted perfectly. Usually indicates the age of individuals past their late teens to early twenties.(Nelson and Ash, 2010). The presence of visible impacted third molars in the

mandible can provide information about the population. East Asian populations (such as Hong Kong) and some ethnic groups in Indonesia (Bugis, Toraja, and Java) have been reported to have a very high prevalence of mandibular third molar impaction compared to other populations. Genetic factors, jaw shape, and dental arch morphology are the main causes of the high rate of impaction in these racial groups (Chu F et al, 2003; Sahetapy et al, 2015; Septina F et al, 2021). The discovery of teeth that are not in their place is likely due to mishandling by officers when taking and collecting the skeleton findings. The decay process allows teeth to easily fall out of their sockets. Officers who lack dental knowledge could place loose teeth in the incorrect tooth sockets.




Figure 9. left view of mandible

Found the angle of the jaw (angulus mandible) around 123° , a hole was found in the jaw bottom (mental foramen) approaches mid-jaw bone, no fracture was found (figure 9). Shovel shape insisivus was seen in left and right maxillary second insisivus (figure 7), it can referred that the skeletal was Mongoloid. (Ling & Wong, 2008).

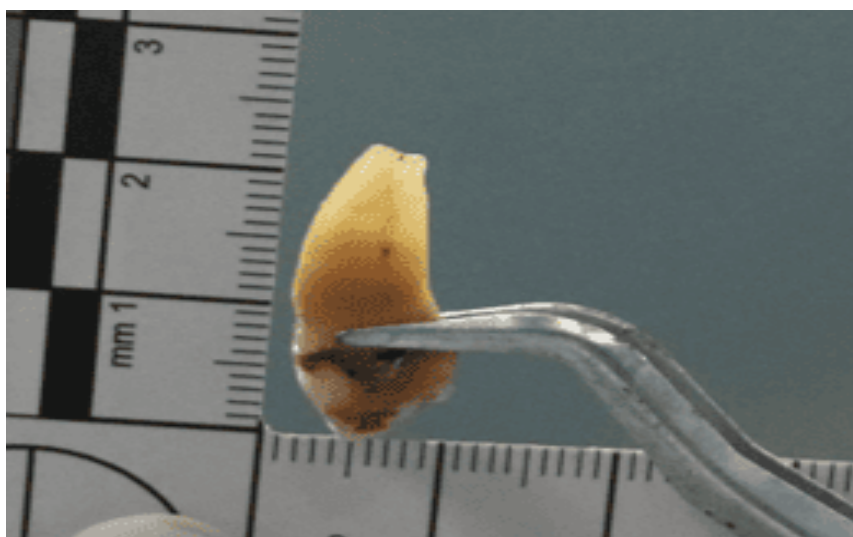


Figure 10. Tooth 34 for translucency analysis

For age estimation using translucency from tooth root, the photographs were taken employing the ABFO number two scales based on Interpol's guidelines for photographic documentation of post mortem. In this case we make analysis from teeth 34 using formula by Lamendin¹⁰ (figure 10). The age estimation was 49.21 years with a standard deviation of 13.4 years. Age estimation also can analysed from palatal suture in figure 7. The sutura insisiva, posterior

median palatine and transverse palatine has closed, only anterior medial palatine suture has not closed yet. From that we can analyze that the age from skeletal was 30 years until 50 years. (Carazo, 2017)

As a note, the author cannot describe the complete bone findings, for example the number of ribs, long bones and pelvic bones found as in the standard approach of Buikstra, J.E. & Ubelaker, D.H. (1994) or Bass's "Human Osteology", because the author only took part in the field of forensic odontology, limited to the skull and mandible.

Result and Discussion

The First Determination is to Ensure that the Part of the Bone is of Human Origin or Not.

Bones can be distinguished from one another primarily based on their anatomical shape, with particular emphasis on the morphology of larger bones like those found in the skull, long bones and pelvic bones. If bones are found, sometimes the bones of certain animals are similar to human bones. (Sihaloho & Linggom, 2022) Human bones differ from animal bones in terms of structure, thickness, size and age of ossification. Every human has 206 bones, and these bones are divided into long, short, flat and irregular bones. In general, the adult skeleton has two basic bone structural components, namely spongiosa and compact/cortical. Human bones differ from animal bones in terms of structure, thickness, size, and age of ossification. It is necessary to see the fusion of the epiphysis and metaphysis as well as the size of the bone, bone density, which can also be done with serological examination (precipitin test). (Parinduri, 2018)

The skull is a part of the bone that is relatively easier to distinguish in terms of shape (architecture) between humans and non-humans (Koesbardiati T, et al, 2017).



Figure 11. Differences between animal and human skulls (Koesbardiati T, et al, 2017)

Determining Whether It Comes from One Person or More

Minimum Number of Individuals (MNI) is a method used in the analysis of skeletal finds to estimate the minimum number of individuals that may be represented in a collection of bones or fragments found. MNI aims to avoid overcounting due to the presence of bones or body parts that are fragmented and scattered so that they are not counted as separate individuals. For the zonation system, the bones are separated into three to fifteen zones, with the exception of those found in the skull. Nevertheless, each skull bone is represented by a distinct zone. (Lambacher et al, 2016). In this case, as a forensic

odontologist we found only one skull and mandible in the body bag, which were still attached, indicated that it from a single individual, but to determine the minimum number of individuals must look at other bone findings analyzed by forensic anthropologists.

Determining Gender

In this case we can be inferred from the anatomical shape of the skull bones such as the relatively sloping forehead bone, protruding of glabella, the relatively square orbital cavity analysed as a male. The mandibular arch tends to be wide and shaped like the letter 'U', the wide chin, this all indicates that this skeleton is male. (Burns, 2013; Sihaloho & Linggom, 2022) Based on study by Chusida et al (2024) The measurement of gonial angle was not significant for determining gender. (Chusida et al., 2024)

Determining Race

For racial examination, the results obtained, relatively high & narrow nose, shovel shape teeth, wide palate, simple elliptical curve of dental row, straight transverse palatine suture, which indicates the characteristics of the Mongoloid race. (Byers, 2017) We also can analysed race from orbital index. Orbital index classified into three categories: (a) Megaseme (large), the value is 89 or over, this type is characteristic of Mongoloid, (b) Mesoseme (intermediate), the range between 83 and 89, this type was found in Caucasoid, (c) Microseme (small), the value is 83 or less, this type of Negroid. (Kumar & Nagar, 2014)

Age Estimation

In forensic odontology, estimating age was the key aspect of forensic odontology from the fact that human dental development follows a consistent and dependable pattern. Various technique for dental age estimation can be employed. Every technique has strengths and weaknesses, and ideally, its is recommended to use more than one technique, repeating measurements and calculations to get best results. Therefore, for dental age estimation, it is essential to look at population-specific differences in geographical regions. Additionally, it is important to document the reliability of the method that used for age estimation concerning chronological age and compare different dental age estimation methods with each other. (Azizah et al., 2024)

Most dental age estimation conducted with dental radiology (Kurniawan et al., 2022), but in condition which can not take the radiography, we can use dental attrition method (Verma et al., 2019). The measurement of root dental translucency from single intact tooth can be done for age estimation if the tooth available. The measurement of root dental translucency in single root tooth with formula from Lamendin can be use in this case as is it fast, easy, and reasonably accurate except this method for cases of individuals under age 40 has large standard deviation, so other method can be considered. (Lamendin et al., 1992)

Age estimation based on palatal sutura was build upon the premise that the obliteration of palatine suture is progressive and linked to age. The obliteration has a specific direction and specific order; it follow a general pattern of obliteration. The sequence of sutural obliteration begins with the suture insisiva, followed by the posterior median palatine suture, then the transverse palatine suture, and ultimately the anterior median palatine suture. The age estimation is based on the last suture exhibiting obliteration. (Carazo, 2017)

Conclusion

From the results of the examination of the case above, it can be concluded that the collection of bones is the bones of a human. The skeleton comes from the Mongoloid race (Asia), male gender, and estimated age is 30-50 years old based on sutura palatine and 49,21 years with Standard Deviation 13,4 years from Lamendin method. When recognizing the skeleton, it takes little work to identify individual, meanwhile, as the organs are no longer accessible, determining the reason of death can sometimes be difficult. The skeleton is an extremely strong and non-degradable part of the human body. To optimize the results for estimating sex, race, and age, it is recommended to use one established method in addition to several methods/measurement formulas that are present throughout the remaining tissue.

References

- Amir A. (2013). *Rangkaian Ilmu Kedokteran Forensik*. (3rd Ed.). Medan: Departemen Kedokteran Forensik Fakultas Kedokteran Universitas Sumatera Utara.
- Azizah, A. N., Yunus, A. D., Puspitawati, R., Soedarsono, N., & Suhartono, A. W. (2024). Dental Age Estimation From Tooth Development: A Literature Review (Metode Estimasi Usia Berdasarkan Perkembangan Gigi: Ulasan Literatur). <https://doi.org/10.54052/Jhd>
- Burns, Karen Ramey. (2013). *Forensic Odontology Training Manual* (Third edition). Pearson
- Carazo, M. S. (2017). *Application of the Maxillary Suture Obliteration Method for estimation of the age at death of prisoners in the Valdenoceda Francoist Prison*. BIOARHEOLOGIJA na Balkanu : 85-90. Retrieved from <https://www.researchgate.net/publication/320558611>
- Chiam, S. L., Higgins, D., Colyvas, K., Page, M., & Taylor, J. (2021). Interpretation, confidence and application of the standardised terms: Identified, Probable, Possible, Exclude and Insufficient in forensic odontology identification. *Science and Justice*, 61(4), 426–434. <https://doi.org/doi:10.1016/j.scijus.2021.02.007>
- Chu F, Li T, et al. 2003. Prevalence of Impacted Teeth and Associated Pathologies - A Radiographic Study of the Hong Kong Chinese Population. *Hong Kong Medical Journal*. 9(3); 158–163. <https://pubmed.ncbi.nlm.nih.gov/12777649/>
- Chusida, A., Kurniawan, A., Rizky, B. N., Pribadi, S. N. P., Diva, A. T., Anandhiyah, H. D., & Alias, A. (2024). Gonial angle and mandibular ramus height in Surabaya population: comparison and correlation analysis in panoramic radiograph. *Majalah Kedokteran Gigi Indonesia*, 10(2), 116. <https://doi.org/doi:10.22146/majkedgiind.98837>
- Divakar, K. P. (2017). *Forensic Odontology: The New Dimension in Dental Analysis*. *INTERNATIONAL JOURNAL of BIOMEDICAL SCIENCE* (Vol. 13). Retrieved from www.ijbs.org
- Franklin, D. (2010, January). Forensic age estimation in human skeletal remains: Current concepts and future directions. *Legal Medicine* : 1-7. <https://doi.org/doi:10.1016/j.legalmed.2009.09.001>
- Henky, & Safitry, O. (2012). Identifikasi Korban Bencana Massal: Praktik DVI Antara Teori dan Kenyataan. *Indonesian Journal of Legal and Forensic Sciences*, 2(1), 5–7. Retrieved from <http://ejournal.unud.ac.id/>
- Hughes, C., Yim, A. D., Juarez, C., Servello, J., Thomas, R., Passalacqua, N., & Soler, A. (2023). Investigating identification disparities in forensic anthropology casework. *Plos one*, 18(11), e0290302. <https://doi.org/10.1371/journal.pone.0290302>
- Koesbardiati, T; Murti, DB; Putri, RZ (2017). Petunjuk Identifikasi Rangka Manusia. Direktorat Cagar Budaya dan Museum, Kemendikbud RI : 37.
- Kumar, A., & Nagar, M. (2014). Morphometry Of The Orbital Region: ‘Beauty Is Bought By Judgment Of The Eyes.’ *Int J Anat Res*, 2014(3), 566–570. Retrieved From [Www.ljmr.org/Ijar.Htm](http://www.ljmr.org/Ijar.Htm)
- Kurniawan, A., Chusida, A., Atika, N., Gianosa, T. K., Solikhin, M. D., Margaretha, M. S., ... Marya, A. (2022). The Applicable Dental Age Estimation Methods for Children and Adolescents in Indonesia. *International Journal of Dentistry*. Hindawi Limited. <https://doi.org/doi:10.1155/2022/6761476>

- Lambacher, N; Radonic, KG; Bonthorne, E; Montero, FJVT. (2016). Evaluating three methods to estimate the number of individuals from a commingled context. *Journal of Archaeological Science: Reports* 10 : 674–683. <https://doi.org/10.1016/j.jasrep.2016.07.008>
- Lamendin, H., Baccino, E., Humbert, J. F., Tavernier, J. C., Nossintchouk, R. M., & Zerilli, A. (1992). *A Simple Technique for Age Estimation in Adult Corpses: The Two Criteria Dental Method*. *Journal of Forensic Sciences* (Vol. 37).
- Ling, J. Y. K., & Wong, R. W. K. (2008). *Incisal Morphology of Southern Chinese*. *The Open Anthropology Journal* (Vol. 1).
- Nelson & Ash, 2010. *Wheeler's dental anatomy, physiology and occlusion*. Ninth edition : 31. Saunders Elsevier.
- Novitasari, D., Istiqomah, & Rizaldy, R. (2023). Identifikasi Antropologi Forensik Pada Investigasi Kasus Temuan Rangka Manusia - Case Series. *Prosiding Kongres XV & HUT Ke -52 PAAI 2023 -4th LUMMENS. 'The Role of Gut-Brain Axis in Indonesian Human Development'*.
- Parinduri, A. G. (2018). IDENTIFIKASI TULANG BELULANG. *Anatomica Medical Journal Fakultas Kedokteran*. Retrieved from <http://jurnal.umsu.ac.id/index.php/AMJ>
- Republik Indonesia. (2009). Undang-Undang Republik Indonesia Nomor 36 Tahun 2009 tentang Kesehatan. Jakarta: Republik Indonesia
- Sahetapy DT, Anindita BS, Hutagalung K. 2015. Prevalensi Gigi Impaksi Molar Tiga Partial Erupted pada Masyarakat Desa Totabuan. *Jurnal e-GiGi (eG)*, 3(2); 641–646. <https://ejournal.unsrat.ac.id/index.php/egigi/article/view/10810/10399>
- Septina F, Apriliani A, Baga I. 2021. Prevalensi Impaksi Molar Ketiga Rahang Bawah di Rumah Sakit Pendidikan Universitas Brawijaya Tahun 2018. *E-Prodentia Journal of Dentistry*, 5(2); 450–460, <https://doi.org/10.21776/ub.eprodenta.2021.005.02.1>
- Sihaloho, K., & Linggom, T. (2022). IDENTIFIKASI TULANG BELULANG, 12(1), 37–44. doi:10.46880/methoda.Vol12No1.pp37-44
- Verma, M., Verma, N., Sharma, R., & Sharma, A. (2019). Dental age estimation methods in adult dentitions: An overview. *Journal of Forensic Dental Sciences*, 11(2), 57. https://doi.org/10.4103/jfo.jfds_64_19