



## Morphological and Morphometric Analysis of Orocraniofacial Bones for Estimative Identification Gender

Wulan Purnama Sari<sup>1</sup>, Nurtami Soedarsono<sup>2</sup>, Ria Puspitawati<sup>2</sup>

<sup>1</sup>Graduate Student at Division of Forensic Odontology, Department of Oral Biology, Faculty of Dentistry, University of Indonesia, Jakarta, Indonesia

<sup>2</sup>Division of Forensic Odontology, Department of Oral Biology, Faculty of Dentistry, University of Indonesia, Jakarta, Indonesia

\*Corresponding Author: Wulan Purnama Sari

Email: [nurtami@ui.ac.id](mailto:nurtami@ui.ac.id)



### Article Info

#### Article history:

Received 5 February 2024

Received in revised from 28 February 2024

Accepted 13 March 2024

#### Keywords:

Morphological Analysis

Morphometric

Identification

Sex Estimation

### Abstract

Identification of sex estimation is the first step in the identification process and is one of the priority parameters in the forensic identification process. Identification is made when the condition of the body is unrecognizable due to natural disasters, transport accidents, bomb explosions, ethnic studies and crime investigations, where only a few parts of the body are already incomplete and limited information are available. In forensic odontology, morphological and morphometric analysis of the orocraniofacial bone is an important component that can help in the process of identifying sex estimation because it has different shapes and sizes in each individual and population. This article will discuss morphological and morphometric analysis of several parameters of the orocraniofacial bone, as well as the advantages and limitations of both methods.

## Introduction

Sex estimation is an important parameter and is a top priority in forensic identification processes and forensic anthropology (Franklin et al., 2014). Identification is made when the condition of the body is no longer recognizable due to natural disasters, transportation accidents, bomb explosions, ethnic studies, legal interests, and crime investigations, when only skeletal remains are found and limited information is available (Vidya et al., 2013). Based on Indonesian legal regulations, Health Law No. 36 of 2009 states that it mandates the government and communities to make identification efforts on bodies that cannot be identified. Identification efforts must be through high precision in order to fulfill the human rights to identity, dignity and social status, religion, legal and other social issues (Vidya et al., 2013; Nagare et al., 2018). Identification is carried out in the interest of humanity by fulfilling the rights of the victim to be returned to his family and buried in accordance with his religion.<sup>4</sup>

Sex estimation is one part of forensic odontology, which can help other experts in determining the estimated sex of the body using skull bones based on various differences in skull patterns and skull characteristics of the two sexes (Nagare et al., 2018). Gender identification is the first step in an identification process, as it can eliminate about fifty percent of the population in an identification process that will be followed by the identification of estimated age, race, and height (Vidya et al., 2013; Nagare et al., 2018; Wankhede et al., 2015).

Sex estimation identification using the pelvic bone has a high accuracy of 95% because it is the first best bone in the sex identification process, however, the pelvic bone is not always available intact so it is difficult to analyze.<sup>6</sup> Several studies have shown that the skull bone is an indicator that shows excellent sexual dimorphism after the pelvic bone with an accuracy of

92%. This bone has a high resistance to environmental conditions and is a good indicator of gender identification (Mahakkanukrauh et al., 2015; Sheta et al., 2015; Sukre et al., 2017).

Estimation of sex using skeletal remains is influenced by various factors such as environment, hormones, and muscle activity during life that can affect the human skeleton (Sheta et al., 2015; Taylor & Kieser, 2016). Thus, accuracy is needed in sex estimation based on systematic assessment and the degree of sexual dimorphism indicated by the skeleton. In general, there are two osteological methods in determining the estimation of individual sex, namely morphological and morphometric methods (Wankhede et al., 2015; Mahakkanukrauh et al., 2015). Physical anthropology uses morphological and morphometric aspects to estimate and explain the characteristics of individuals based on the condition of the bones found (y de la Rama Mandibular, 2022).

Morphological analysis is a direct visual observation of the skeleton without the help of tools and is subjective (Wankhede et al., 2015). Some of the orocraniofacial bone parameters used in morphological identification are the *nuchal crest*, the mastoideus process, the supraorbital margin, the supraorbital ridge, and the eminentia mentalis. Walker's 2008 study looked at 304 individuals from white modern Americans and Britons, and *Native Americans*. From the results of the study, it was found that supraorbital ridge, mental eminence, and mastoideus process can predict sex with an accuracy of 87% (Berg, 2013). However, this morphological examination is subjective because it is only based on the researcher's direct observations based on observed morphological features (Wankhede et al., 2015).

The morphometric method is a direct measurement of several measurement parameters on the skeleton using measurement tools. Several studies have been conducted in different parts of the world in various populations using orocraniofacial parameters to produce accuracy in sex estimation in an individual. Measurements of skull bones first explored by Giles and Elliot in 1963 yielded a relatively high accuracy rate (80%–90%). These measurements are based on other studies of the world's population (cf Giles 1970; Howells 1973, 1989). When a complete skull is not found, it can use fragments from the base of the skull for sex estimation (Holland 1986) (Berg, 2013).

The results of morphological and morphometric analysis accuracy using several orocraniofacial bone parameters resulted in different accuracy compared to using one parameter. Therefore, several variations of measurement parameters of the orocraniofacial bone are needed to improve the accuracy of the examination. Various orocraniofacial morphometric parameters have been widely studied. However, the data obtained for this sex estimation are specific to each population, so further research is needed in each population (Sheta et al., 2017). The purpose of this article is to analyze morphological and morphometric methods on orocraniofacial in the estimation of individual sex.

### **Morphological Analysis of Orocraniofacial Parameters in Sex Estimation**

Morphological Analysis is a method of direct visual observation carried out by researchers. Human skull bones have multiple morphologies that show sexual dimorphic and resistant to damage and decay processes, so that several elements of the skull can be examined in estimating sex. In general, the skull bone has a larger size in males compared to females which appears smaller and smoother.

### **Morphological Analysis of Buikstra and Ubelaker**

The morphological features of Buikstra and Ubelaker are generally determined and given a scoring system based on *the Standards for Data Collection from Human Skeletal Remains* (Salo

et al., 1994) using five observed morphologies, namely *nuchal crest*, mastoideus processus, supraorbital margin, supraorbital ridge / glabella area, and *mental eminence*. Salo et al. (1994) rated observations ranging from 1 (female) to 5 (male).

*Nuchal crest* or better known as occipital protuberantia is a part that is anatomically located posterior to the skull. Morphological observations appear in males to show greater morphology and have *inion hooks*, while in females *nuchal crest* appears smooth and without prominent protrusions (Figures 1A and 1B).

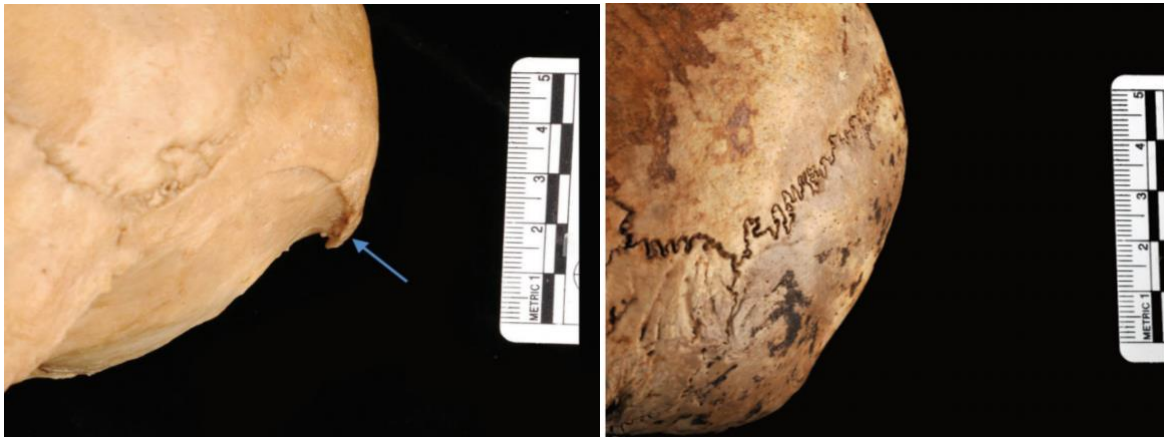

Figure 1. A. *Nuchal crest male (value 5)*. B. *Women's nuchal crest looks smooth without bulges (value 1)*

The second morphological observation section is the mastoideus processus, in this section it shows in males to have a wider and longer shape in relation to the externus acoustic meatus. In females the mastoideus processus appears smaller and shorter (Figures 2A and 2B).

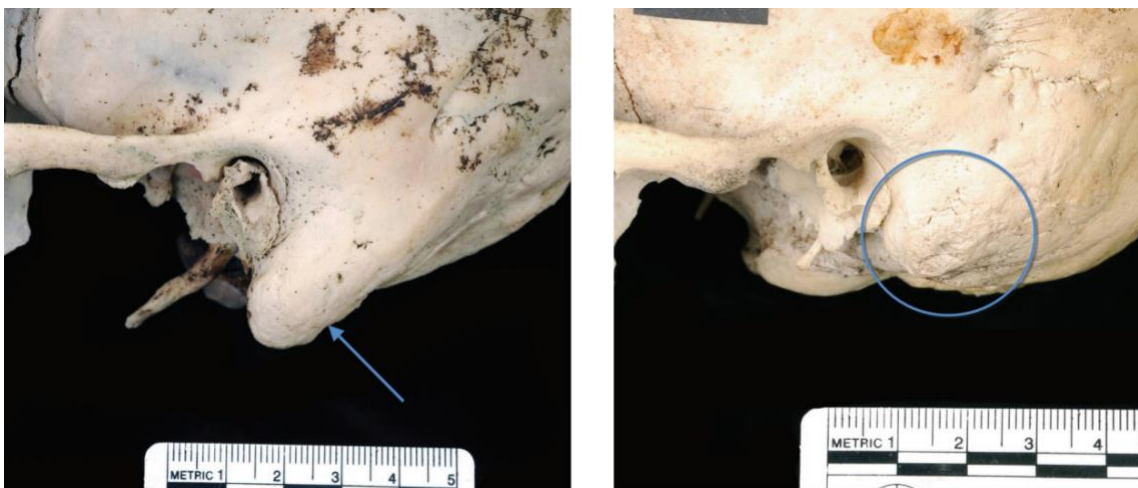

Figure 2. A. *Proc. Mastoideus Male (value 5)* B. *Proc. Mastoideus female (value 1)*

The supraorbital margin will usually appear more rounded and blunter in males while in females it appears more angular creating sharp contours (Figures 3A and 3B). The supraorbital ridge / glabella area in males appears much more prominent so as to show heavy bony protrusions, in females the glabella tends to be relatively flat (Figures 4A and 4B).




Figure 3. A. Male supraorbital margin (score = 5) B. Female supraorbital margin (value 1)




Figure 4. A. Male glabella area (value = 5) B. Female glabella area

The last morphological observation part that can be observed is mental *eminence* located in the anterior mandible. *Mental eminence* in men shows a massive bone shape, while in women this area tends to be smooth and less prominent (Figures 5A and 5B).

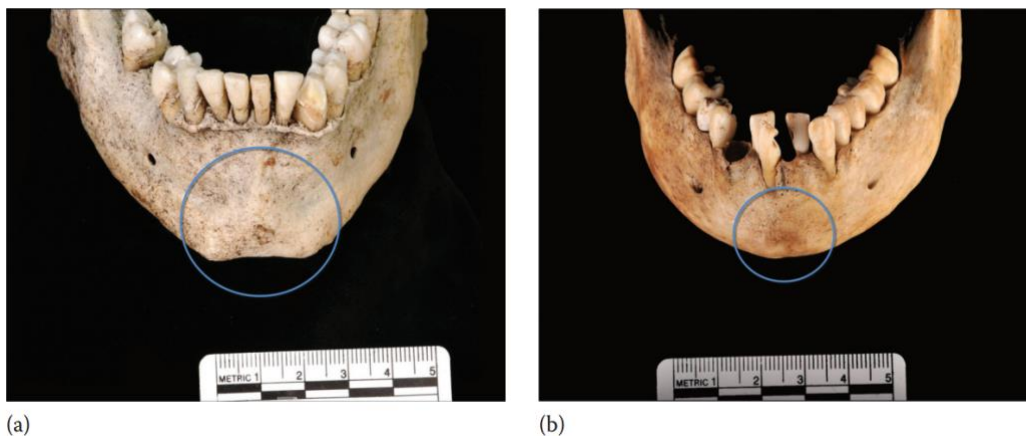


Figure 5. A. male mental eminence (value = 5) and square B. Female mental eminence (value = 1/2) is smaller and V-shaped (Berg, 2013)

## Morphological Analysis of Ferembach et al. (1980)

Analysis This method uses a five-point scale determined through observations on each of the diagnostic features. The numerical values used are -2 to +2, which denote *hyperfeminine and hypermasculine*, respectively. The morphological portion observed based on its significance and multiplied by one, two, or three, is then averaged to determine the estimated sex. This method has the advantage of precision and effectively sorts the importance of certain parts. Roberts et al. (2014) contributed to describing character traits in detail as well as comparative numbers in the sex estimation methodology of Ferembach et al. (1980). These two complementary approaches can easily be used together (Figure 6).

























Trait	Weight	Sexualization				
		Hyperfeminine (-2)	Feminine (-1)	Indeterminate 0	Masculine (+1)	Hypermasculine (+2)
Glabella 	3	smooth 	slightly delimited 	delimited 	marked 	massive, prominent 
Mastoid process 	3	very small 	small 	medium 	large 	very large 
Nuchal plane	3	smooth	slightly arched traces of nuchal lines	nuchal lines and occipital crest evident	nuchal lines and occipital crest marked	nuchal lines and occipital crest with rough surface
Zygomatic process of the temporal	3	very thin and low	thin and low	medium	thick and high	very thick and high
Superciliary arches	2	smooth	slightly delimited	delimited, marked	marked	very marked
Frontal and parietal eminences	2	marked	medium	moderate	indistinct	missing
External occipital protuberance 	2	smooth 	hardly 	medium 	marked 	very marked 
Zygomatrics	2	very low, smooth surface	low, smooth surface	medium, irregular surface	high, irregular surface	very high, irregular surface
Frontal profile	1	vertical	almost vertical	little inclined	medium inclined	strongly inclined
Orbital form 	1	very round, sharp border 	round, sharp border 	transitory form, medium border 	quadrangular, rounded border 	very quadrangular, rounded border 

Figure 6. Modification of Ferembach et al. (1980) and Salo et al. (1994).<sup>12</sup>

## Morphological Analysis with Walker Assessment Technique

Walker's assessment was carried out using cranial features that had been described by Salo et al. (1994), namely, supraorbital ridge or glabella area, supra-orbital margin, mastoid process, *nuchal crest*, and *mental eminence*. Walker's grading system uses a 5-level ordinal scale with the following value division: 1 or 2 belong to the feminine category, 3 are ambiguous/uncertain categories, and 4 or 5 are masculine. The lower the value, the fewer traits appear in the morphology/minimal expression in the observed bone with a value of 1, while a value of 5 will indicate maximal morphology/expression (Figure 7) (Malek et al., 2023; Cappella et al., 2022).

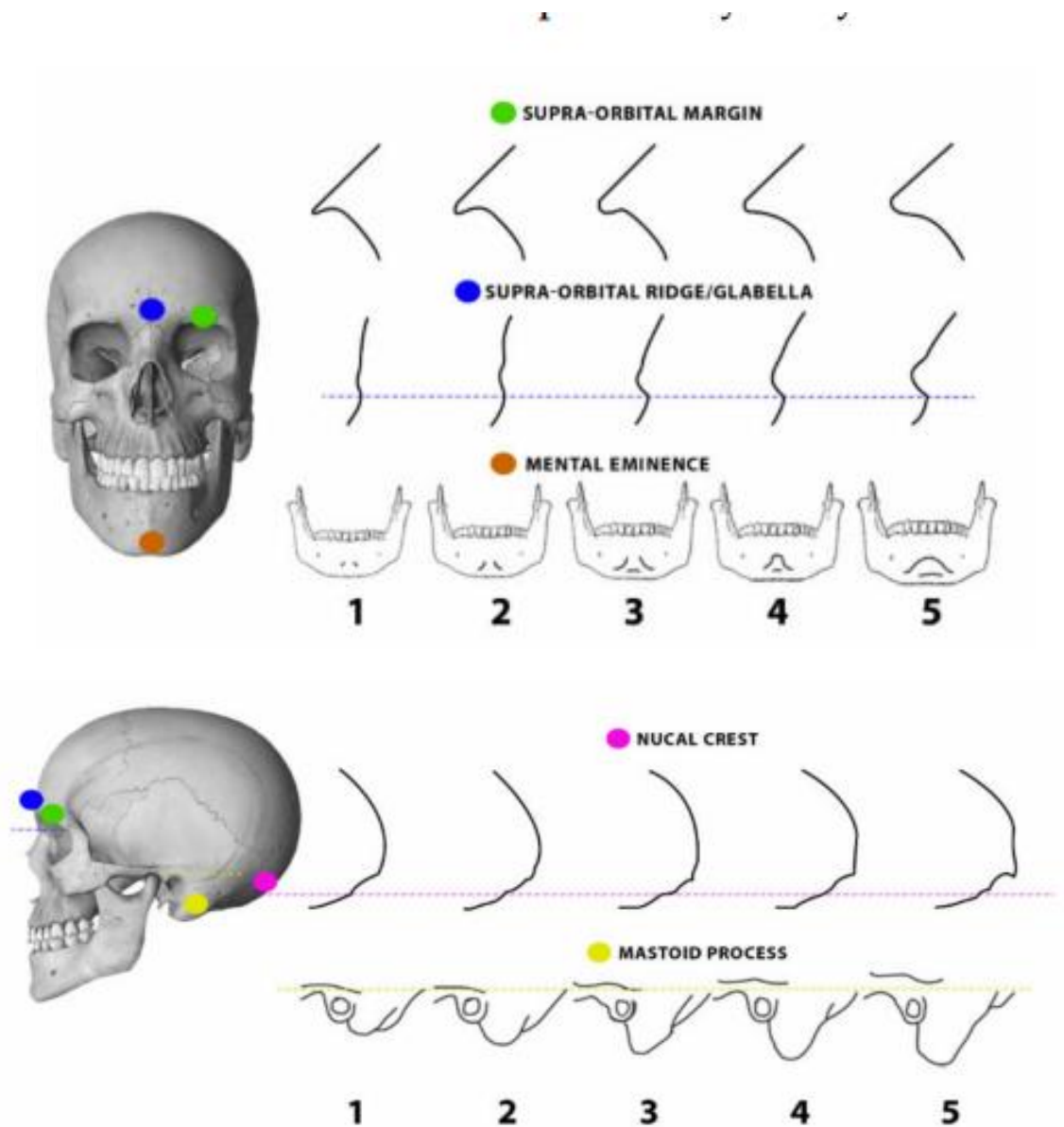


Figure 7. 5-point scale scoring system on the cranial section based on the Walker14 classification

In addition to using the parts described above, there are several parts of morphology that can be observed in estimating sex. One of them is on the orbital bone, on the male orbital bone it looks quadrilateral, while in women it looks more rounded. In addition, the face appears in men to have a taller appearance than in women (Figure 8) (Burns, 2015).

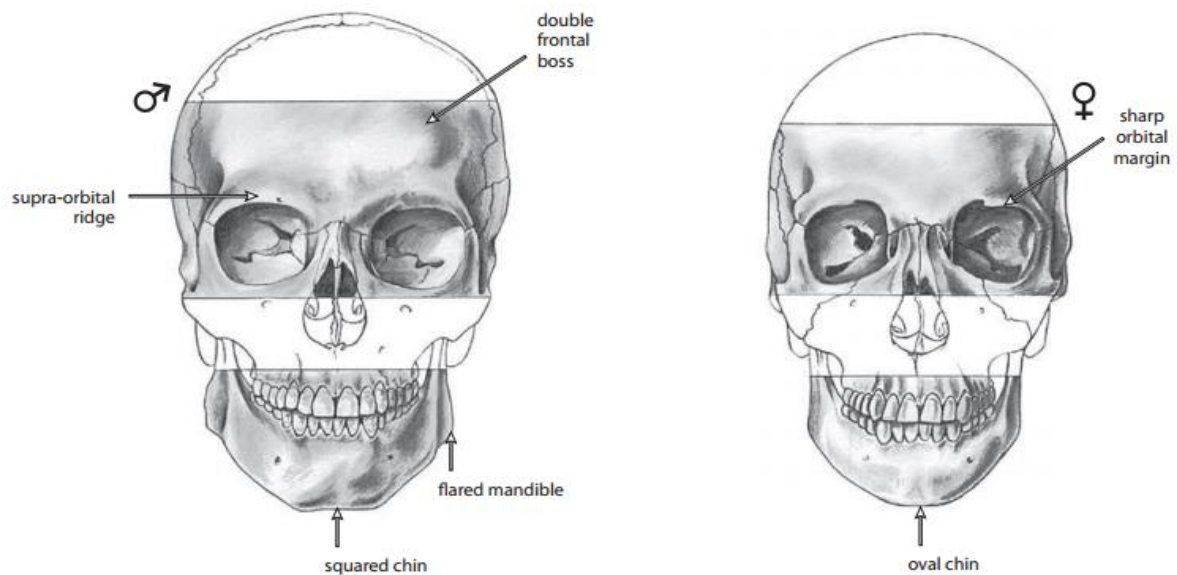


Figure 8. Frontal view. Comparison of Male and Female Skulls

### Morphometric Analysis of Orocraniofacial Parameters in Sex Estimation

Morphometric method is a method of direct measurement on skeletal with the help of measuring instruments to obtain data from a certain population. Morphometric studies have been conducted in various populations using several orocraniofacial parameters in sex estimation. Here are some parameters of orocraniofacial bone used in sex estimation.

#### Foramen Magnum

The foramen magnum is an important structure in sex estimation and plays a role in growth and development. Foramen magnum in some studies has parameter points that can be used for sex estimation, namely: (1) Antero-posterior diameter: basion point – opisthion point; (2) Transverse diameter: measurement between the 2 most lateral points of the foramen magnum. Foramen magnum area: Radinsky (FMA):  $\frac{1}{4} \times X \text{ FML} \times \text{FMW} \pi$ . Foramen magnum index: foramen magnum width  $\times 100$  / foramen magnum length (Singh Bharati et al., 2016).

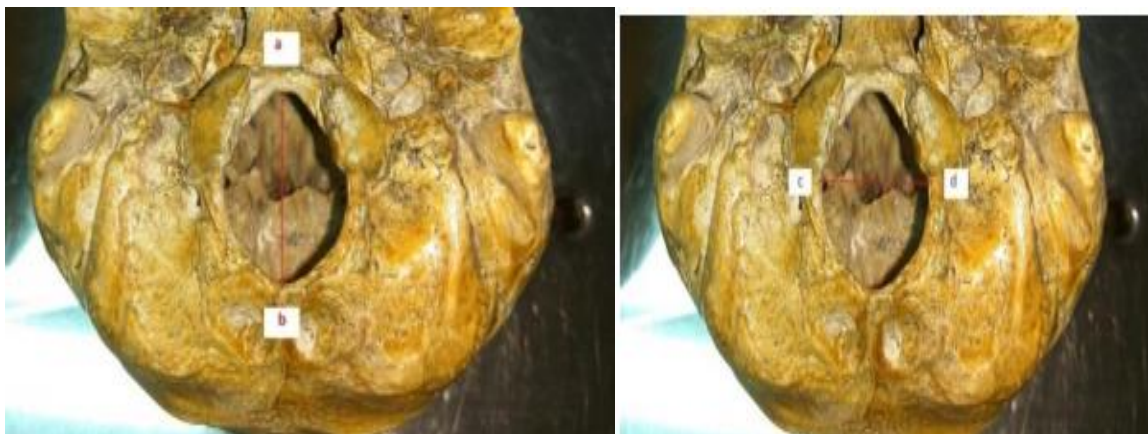

Figure 9. Point a (basion) - b (opisthion) and point c - d

## Palate and Cranial Base

The palate bone is a thin, L-shaped bone that grows from two articulated membrane ossification centers with the posterior maxilla. The bones of the palate will form the palate and ground floor of the nasal cavity. In addition, it also contributes to many internal facial structures, including oral cavity, nasal passages and orbits, as well as important in speech articulation (Burns, 2015; Jacob et al., 2016).

Here are the measurement parameter points on the palate bone and cranial base: (1) Foramen incisor - foramen palatine major right (IF-RGPF); (2) Foramen Insisivus - left major palatine foramen (IF-LGPF); (3) Right major palatine foramen - left major palatine foramen (RGPF-LGPF); (4) Basion – foramen incisor (Ba-IF); (5) Foramen incisor – the central point of an imaginary line joining from the foramen palatine major right and left (IF-RGPF/LGPF) (Lima et al., 2012).

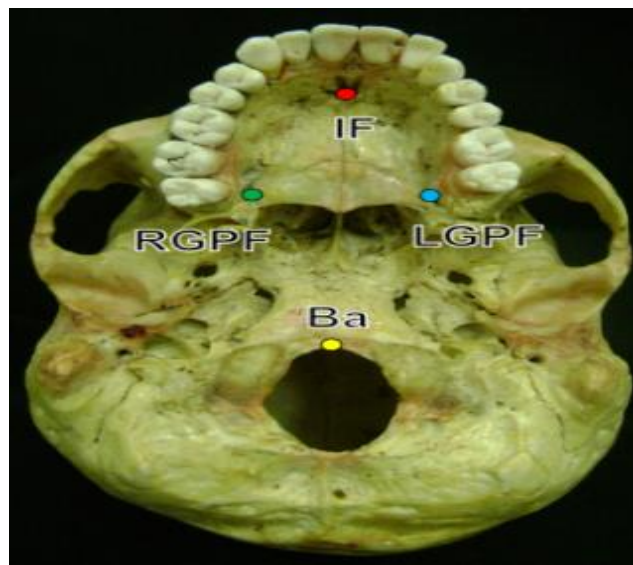
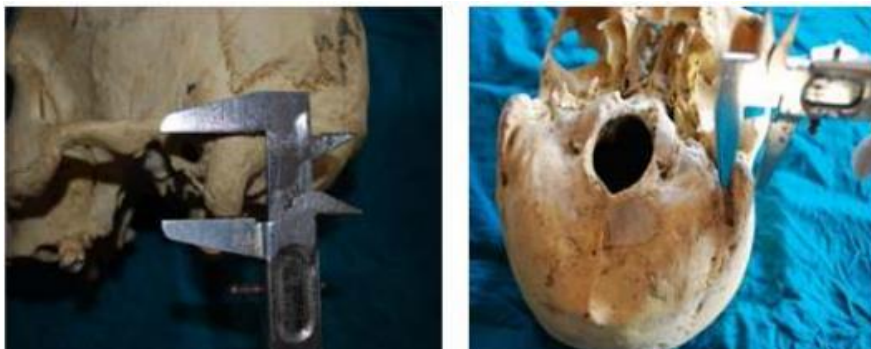

Figure 10. Anthropometric points of the palate and cranial base

## Mastoideus Processus

The mastoideus process is a prominent prominent bone located posterior inferior to the external acoustic meatus. The mastoideus process has good resistance and is the most protected part of the skull. Some of the parameters that have been carried out include: mastoideus length, media-lateral diameter, antero-posterior diameter, mastoideus process index, anterior - mastoideus process, asterion - porion - mastoideus process (Sukre et al., 2017).



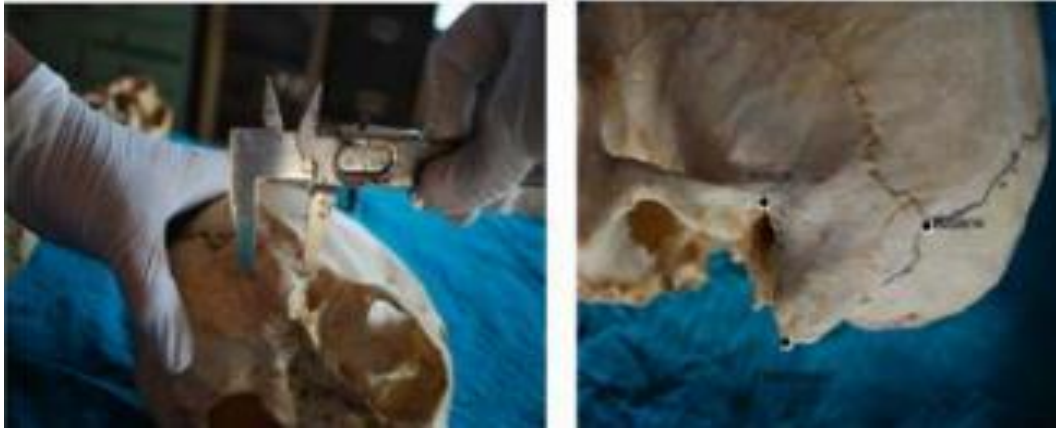

Figure 11. Parameters of the mastoideus process

## Results and Discussion

Gender estimation is a major aspect of identification. Identification is carried out for the benefit of humanity by fulfilling the rights of victims, namely so that they can be returned to their families and buried in accordance with their religion (Sukre et al., 17). In addition, for the sake of law and civil investigation. Gender identification is the first step in an identification process, as it can eliminate about fifty percent of the population in an identification process that will be followed by the identification of estimated age, race, and height (Vidya et al., 2013; Nagare et al., 2018; Wankhede et al., 2015).

Sex estimation using the skull bone shows excellent sexual dimorphism after the pelvic bone because it has a high resistance to environmental conditions and is a good indicator of sex identification.<sup>10,11</sup> In general, there are two osteological methods in estimating the sex of individuals, namely morphological and morphometric methods (Wankhede et al., 2015; Mahakkanukrauh et al., 2015).

Morphological analysis is carried out by direct observation of the shape of the bone to be studied. Research conducted by Kuminski, et al. (2014) at the Wiener Lab Collection Athens, researcher Eliopoulos made observations using 9 morphological features of skulls on 202 individuals from the Athena collection. The results of morphological analysis showed low accuracy for all morphological features studied (Chovalopoulou et al., 2022). This study contrasts with Walker's Research in 2008, which included 304 individuals in white modern American and British, and Native Americans. From the results of the study, it was found that supraorbital ridge, *mental eminence*, and mastoideus process can predict sex with an accuracy of 87% (Berg, 2013).

Morphometric measurements of the foramen magnum were carried out by two researchers, namely Kumar et al. (2015). Aghakhani et al. (2016) conducted a study using 4 parameters of foramen magnum, namely foramen magnum length, foramen magnum width, foramen magnum area, and foramen magnum index on 40 skull bones of andhra pradesh population with an age range of 18-70 years. The results showed that the average transverse diameter of men was 26 mm, in women it was 25.03 mm. The average anteroposterior diameter of males is greater at 30 mm, in females at 29.43 mm. The average area of the foramen magnum in males is 616.39 mm<sup>2</sup> and in females is 580.48 mm<sup>2</sup>. Furthermore, the foramen magnum index in men = men was 87.33 and in women 85.54. From the results of this study, all parameters used in showed that measurements in men were greater than women (Singh Bharati et al., 2021).

Kumar et al. (2015), using foramen magnum on 36 adult skull bones in Oman. The results showed the average transverse diameter of the foramen magnum in men was 30.05 mm and in women 29.49 mm. The average anteroposterior diameter is 36.78 mm in males, while in females it is 33.22 mm. Furthermore, the average foramen magnum area in males is 876.88 mm and in females 776.87mm. Measurements on the foramen magnum index showed an average of 89.01 in women and 81.75 in men. From the measurement results, it was found that 3 parameters showed a higher average value in men, except for the average value on the foramen magnum index which showed a higher value in women (Kumar et al., 2015).

Both studies using foramen magnum parameters showed that samples taken in different populations had different measurement results. In the research of Aghakhani et al. (2016), it was found that the foramen magnum index was greater in men than women, while in the research of Kumar et al. (2015), different results were obtained.

The next morphometric research is measurements using parameters of the palate and base of the skull. Laise et al. in 2012, conducted a study using palate bones and skull base on 100 skull bones with an age range of 22-55 years in the Brazilian population. Measurements are made using 5 measurement parameters. The measurement parameters consist of Foramen insisivus - foramen palatine major right (IF-RGPF); Foramen Insisivus - foramen palatine major left (IF-LGPF), Foramen palatine major right - foramen palatina major left (RGPF LGPF), Basion – foramen incisor (Ba-IF), Foramen insisivus – the center point of the joining imaginary lines of the foramen palatine major right and left (IF-RGPF/LGPF). The results of the study of 4 parameters showed statistically significant differences between male and female sexes. Except the distance between the right and left major palatine foramen (RGPF-LGPF). The linear distance Ba-IF is the most statistically significant measurement. The accuracy of sex estimation classification based on each parameter, namely IF-RGPF 65%, IF-LGPF 67%, Ba-IF 65%, IF-RGPF / LGPF 64% (Lima et al., 2012).

Further research using parameters in processus mastoideus was conducted by Sukre et al. in 2017 with samples of 132 human skull bones in the Maratada population using 7 parameters. The results showed that all parameters in the mastoideus process differed significantly between men and women. 6 parameters indicate that the mean value in males is higher than in females, except for the mean mastoideus index. The best parameters are indicated by mastoideus length, medio-lateral diameter, and porion-mastoideus in sex estimation of skeletal remains (Sukre et al., 2017). The measurement of male mastoideus length is higher than female according to research conducted by Orish & Fawehinmi (2020) in the Nigerian population using right and left mastoideus length parameters (Orish & Fawehinmi, 2020). The overall accuracy using the mastoideus variable reached 76%, according to studies on the North Indian population of 76.7% and 90% in the South Indian population (Sukre et al., 2017).

Morphological and morphometric methods are easy to apply, low cost, reliable, and have been described through several other studies. The morphological method is considered more subjective because it is based on direct observations made by researchers. Morphometric methods carried out by measuring metric points are becoming more widely used by many researchers. In addition, morphometric methods are more recommended because they are more objective, and can reduce the subjectivity of researchers (Sheta et al., 2017).

## Conclusion

Gender estimation is an important aspect of identification and is the beginning in determining other identifications such as age, height, and race. Identification using the skull bone is the second-best bone after the pelvis because it has good resistance to damage. The identification

of sex estimation from bones has two methods, namely morphological and morphometric. Analysis of morphological methods can be done on a large number because it only makes direct observations of shapes by researchers. However, morphological analysis is considered too subjective in research because it is influenced by the state of the observer during the study so that high experience is needed from the researcher. The morphometric method is carried out by making direct measurements on the bone using measurement parameter points on the bone using the help of measuring instruments. This method is a more reliable method because it is more objective, reduces the subjectivity of researchers, displays the results of analysis scientifically, and can be reproduced. Sex estimation with morphometric method approach on orocraniofacial bone has many parameter points that can be used for forensic purposes. Of the various morphometric parameters related to sex estimation that have been widely studied, measurements on bones have different results depending on the parameters measured and the population studied. From the study, it was found that the average value in men was greater than women. However, the morphological and morphometric data obtained for sex estimation are specific to each population. So research is needed using parameters that exist in other populations in order to obtain data from various populations in the world, which will later be a reference in an identification of sex estimates in a population.

## References

- Aghakhani, K., Kazemzadeh, N., Ghafurian, F., Soltani, B., & Soltani, S. (2016). Gender determination using diagnostic values of foramen magnum. *Int J Med Toxicol Forensic Med*, 6(1), 29-35.
- Berg, G. E. (2013). Determining the sex of unknown human skeletal remains. *Forensic anthropology: an introduction*, 139).
- Burns, K. R. (2015). *Forensic anthropology training manual*. Routledge.
- Cappella, A., Bertoglio, B., Di Maso, M., Mazzarelli, D., Affatato, L., Stacchiotti, A., ... & Cattaneo, C. (2022). Sexual dimorphism of cranial morphological traits in an Italian sample: a population-specific logistic regression model for predicting sex. *Biology*, 11(8), 1202. <https://doi.org/10.3390/biology11081202>
- Chovalopoulou, M. E., Valakos, E., & Nikita, E. (2022). Skeletal Sex Estimation Methods Based on the Athens Collection. *Forensic Sciences*, 2(4), 715-724. <https://doi.org/10.3390/forensicsci2040053>
- Ferembach, D. (1980). The Epipaleolithic Men of Moita do Sebastião, Portugal. *Physical Anthropology of European Populations*, 329.
- Franklin, D., Cardini, A., Flavel, A., & Marks, M. K. (2014). Morphometric analysis of pelvic sexual dimorphism in a contemporary Western Australian population. *International journal of legal medicine*, 128, 861-872.
- Jacob, M., Bindhu, S., & Avadhani, R. (2016). Sex determination from hard palate measurements using palatine index with reference to its clinical implications. *Indian Journal of Clinical Anatomy and Physiology*, 3(2), 186-188.
- Kumar, A., itesh Dave, M., & Anwar, S. (2015). M Orphom Etric Evaluation Of Foram En M Agnum In Dry Hum An Skulls. *Int J Anat Res*, 3(2), 1015-23.
- Kuminski, E., George, J., Wallin, J., & Shamir, L. (2014). Combining human and machine learning for morphological analysis of galaxy images. *Publications of the Astronomical Society of the Pacific*, 126(944), 959.

- Lima, L. N. C., de Oliveira, O. F., Sassi, C., Picapedra, A., Júnior, L. F., & Júnior, E. D. (2012). Sex determination by linear measurements of palatal bones and skull base. *The Journal of forensic odonto-stomatology*, 30(1), 37.
- Mahakkanukrauh, P., Sinthubua, A., Prasitwattanaseree, S., Ruengdit, S., Singsuwan, P., Praneatpolgrang, S., & Duangto, P. (2015). Craniometric study for sex determination in a Thai population. *Anatomy & cell biology*, 48(4), 275-283.
- Malek, S., Sealy, J. C., & Gibbon, V. E. (2023). Assessment and improvement of sex estimation standards for application in Holocene San and Khoekhoe populations. *International Journal of Osteoarchaeology*.
- Mishra, S., Gupta, U. K., & Khandori, S. (2023). Gender Determination Through the Morphometric Analysis of Foramen Magnum. *Journal of Advanced Zoology*, 44.
- Nagare, S. P., Chaudhari, R. S., Birangane, R. S., & Parkarwar, P. C. (2018). Sex determination in forensic identification, a review. *Journal of forensic dental sciences*, 10(2), 61.
- Orish, C. N., & Fawehinmi, H. B. (2020). Sex determination using mastoid process length in dry skulls of Nigerian population. *MOJ Anat Physiol*, 7(3), 76-78.
- Roberts, M. E., Stewart, B. M., Tingley, D., Lucas, C., Leder-Luis, J., Gadarian, S. K., ... & Rand, D. G. (2014). Structural topic models for open-ended survey responses. *American journal of political science*, 58(4), 1064-1082. <https://doi.org/10.1111/ajps.12103>
- Salo, W. L., Aufderheide, A. C., Buikstra, J., & Holcomb, T. A. (1994). Identification of Mycobacterium tuberculosis DNA in a pre-Columbian Peruvian mummy. *Proceedings of the National Academy of Sciences*, 91(6), 2091-2094.
- Sheta, A., Megahed, H., & Elzaway, E. (2015). Evaluation of Skull Base Parameters in Sex Determination Using Anthropometric Measurements among a Sample of Egyptians. *Ain Shams Journal of Forensic Medicine and Clinical Toxicology*, 25(2), 15-23.
- Sukre, S. B., Chavan, P. R., & Shewale, S. N. (2017). Morphometric analysis of mastoid process for sex determination among Marathwada population. *MedPulse-International Journal of Anatomy*, 1(2), 27-3.
- Taylor, J., & Kieser, J. (Eds.). (2016). *Forensic odontology: principles and practice*. John Wiley & Sons.
- Vidya, C. S., Shamasundar, N. M., Manjunatha, B., & Raichurkar, K. (2013). Evaluation of size and volume of maxillary sinus to determine gender by 3D computerized tomography scan method using dry skulls of South Indian origin. *International Journal of Current Research and Review*, 5(3), 97.
- Wankhede, K. P., Bardale, R. V., Chaudhari, G. R., & Kamdi, N. Y. (2015). Determination of sex by discriminant function analysis of mandibles from a Central Indian population. *Journal of forensic dental sciences*, 7(1), 37.
- y de la Rama Mandibular, M. (2022). Sex Estimation by Metric Analysis of the Angle of Mandible and the Mandibular Ramus: A Systematic Review. *Int. j. morphol*, 40(4), 883-894.